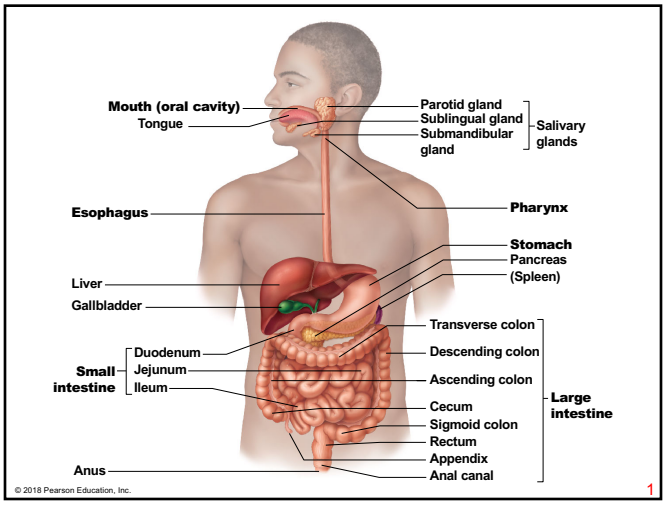
Mouth (oral cavity)
Tongue
Parotid gland
Sublingual gland
Submandibular gland
Salivary glands
Esophagus
Pharynx
Stomach
Pancreas
(Spleen)
Liver
Gallbladder
Transverse colon
Descending colon
Ascending colon
Cecum
Sigmoid colon
Rectum
Appendix
Anal canal
Large intestine
Small intestine
Duodenum
Jejunum
Ileum
Anus
© 2018 Pearson Education, Inc.
1

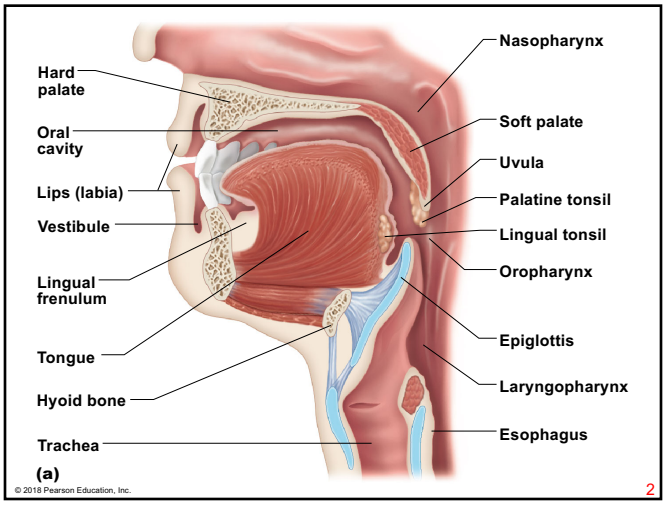
Nasopharynx
Hard palate
Soft palate
Oral cavity
Uvula
Lips (labia)
Palatine tonsil
Vestibule
Lingual tonsil
Oropharynx
Lingual frenulum
Epiglottis
Tongue
Laryngopharynx
Hyoid bone
Esophagus
Trachea
(a)
© 2018 Pearson Education, Inc.
2

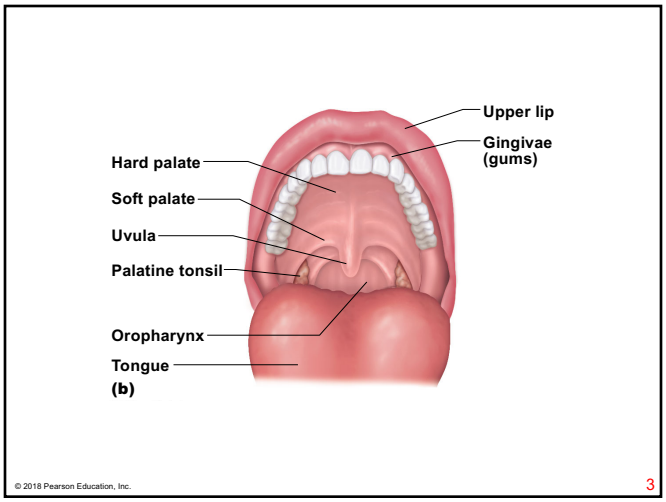
Upper lip
Gingivae (gums)
Hard palate
Soft palate
Uvula
Palatine tonsil
Oropharynx
Tongue
(b)
© 2018 Pearson Education, Inc.
3

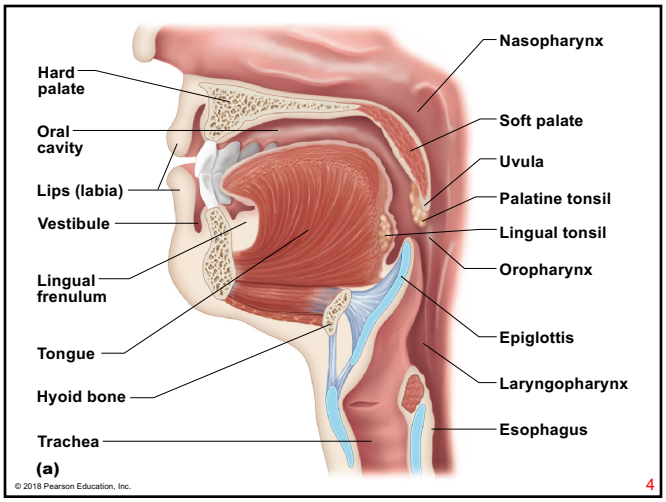
Nasopharynx
Hard palate
Soft palate
Oral cavity
Uvula
Lips (labia)
Palatine tonsil
Vestibule
Lingual tonsil
Oropharynx
Lingual frenulum
Epiglottis
Tongue
Laryngopharynx
Hyoid bone
Esophagus
Trachea
(a)
© 2018 Pearson Education, Inc.
4

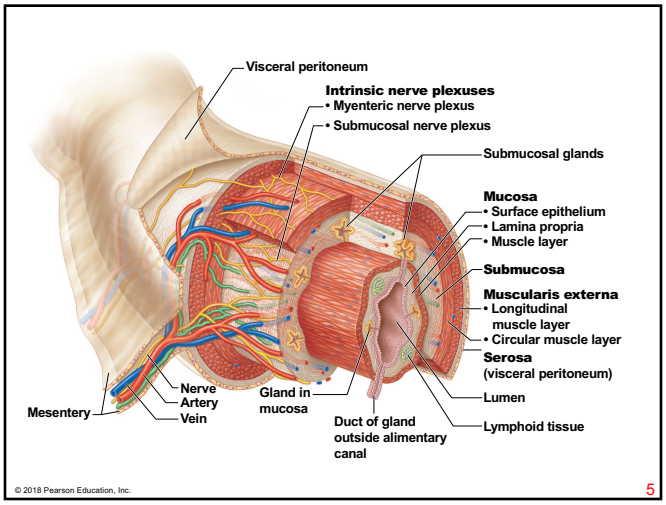
Visceral peritoneum
Intrinsic nerve plexuses
• Myenteric nerve plexus
• Submucosal nerve plexus
Submucosal glands
Mucosa
• Surface epithelium
• Lamina propria
• Muscle layer
Submucosa
Muscularis externa
• Longitudinal muscle layer
• Circular muscle layer
Serosa
(visceral peritoneum)
Lumen
Lymphoid tissue
Nerve
Artery
Vein
Mesentery
Gland in mucosa
Duct of gland outside alimentary canal
© 2018 Pearson Education, Inc.
5

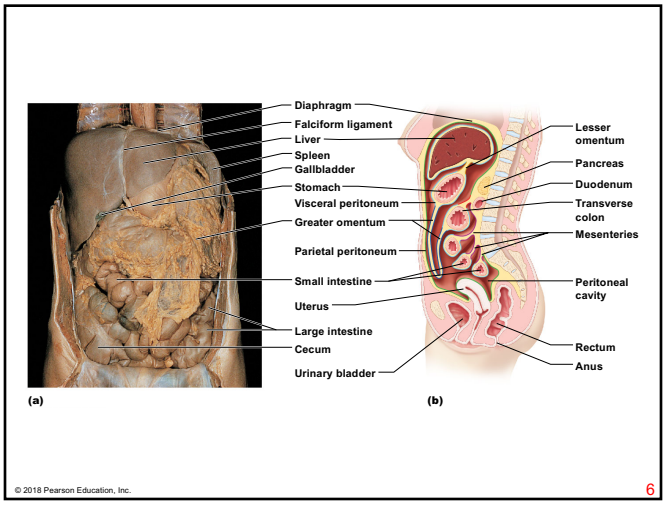
Diaphragm
Falciform ligament
Liver
Spleen
Gallbladder
Stomach
Visceral peritoneum
Greater omentum
Parietal peritoneum
Small intestine
Uterus
Large intestine
Cecum
Urinary bladder
Lesser omentum
Pancreas
Duodenum
Transverse colon
Mesenteries
Peritoneal cavity
Rectum
Anus
(a)
(b)
© 2018 Pearson Education, Inc.
6

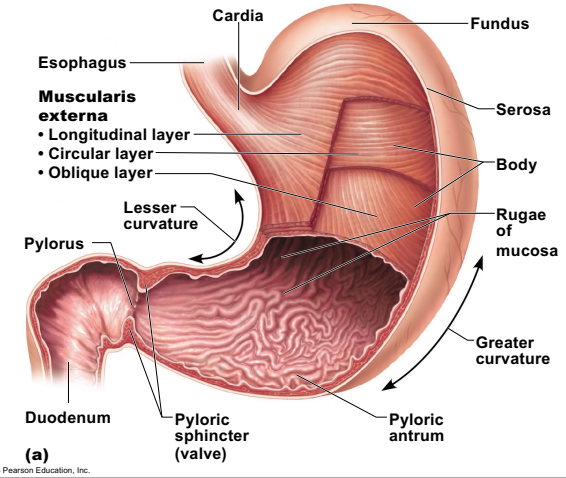

© 2018 Pearson Education, Inc.

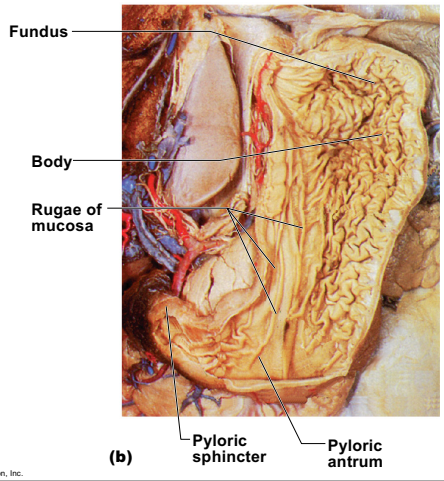

© 2018 Pearson Education, Inc.

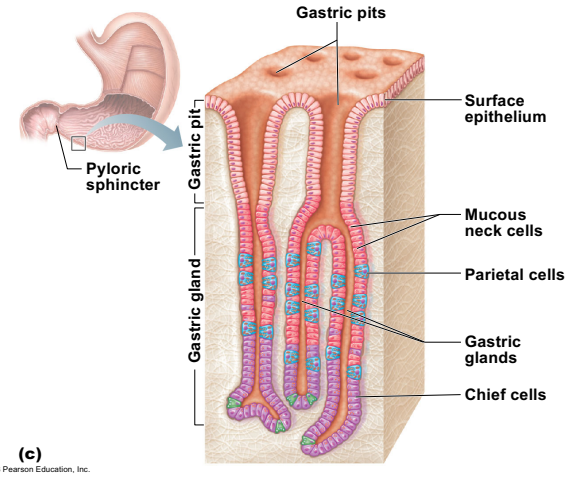

© 2018 Pearson Education, Inc.

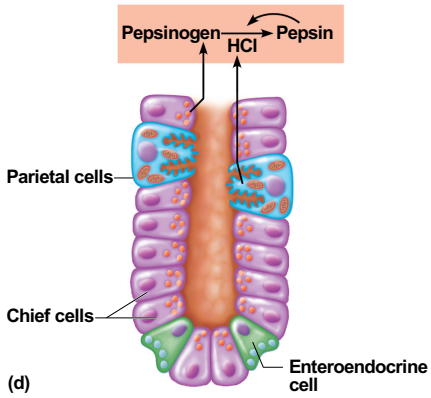

© 2018 Pearson Education, Inc.

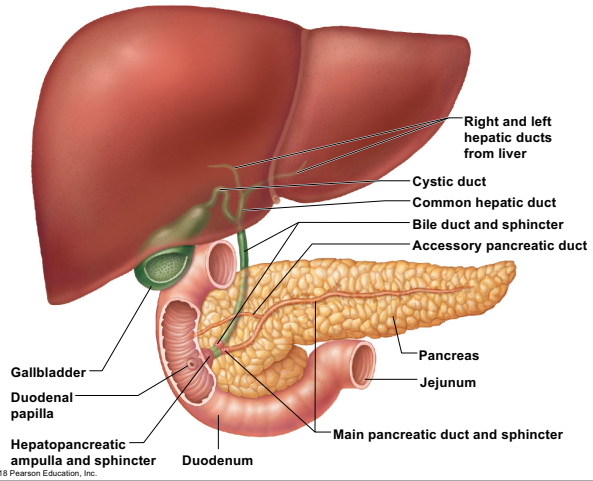

© 2018 Pearson Education, Inc.

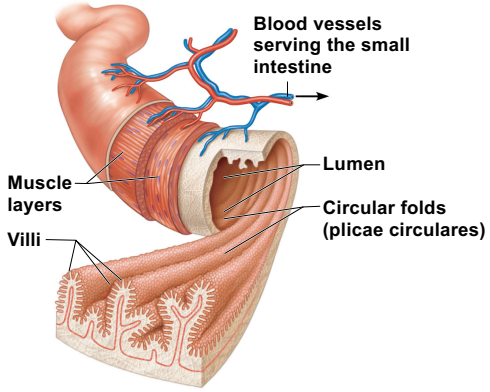

(a) Small intestine

© 2018 Pearson Education, Inc.

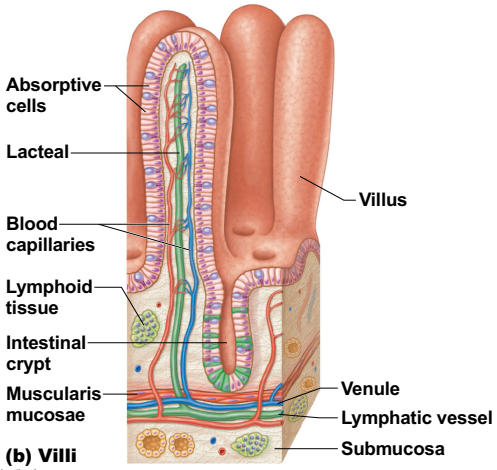

(b) Villi

© 2018 Pearson Education, Inc.

(c) Absorptive cells

© 2018 Pearson Education, Inc.

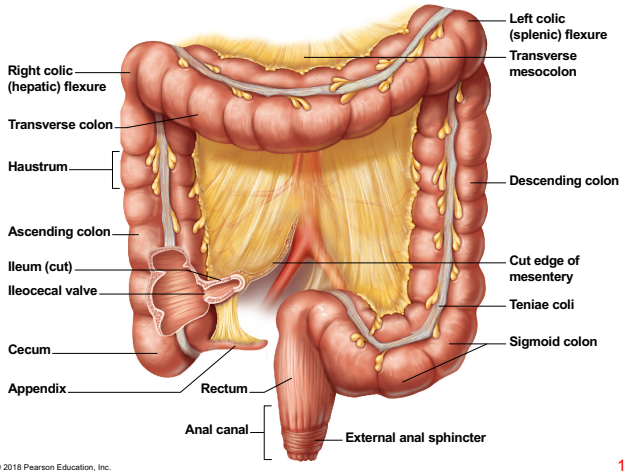

© 2018 Pearson Education, Inc.

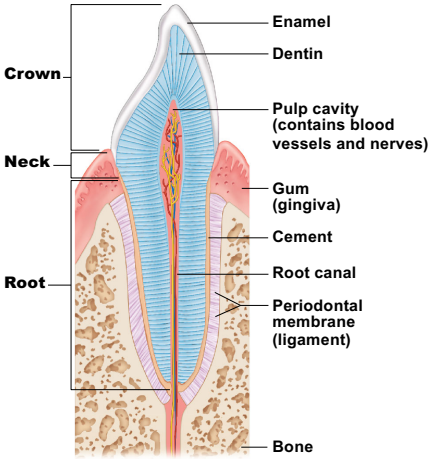

© 2018 Pearson Education, Inc.

Foodstuff	Enzyme(s) and source	Site of action
Digestion of carbohydrates		
Starch and disaccharides		
	Salivary amylase	Mouth
	Pancreatic amylase	Small intestine
Oligosaccharides* and disaccharides		
Lactose, Maltose, Sucrose	Brush border enzymes in small intestine (dextrinase, glucoamylase, lactase, maltase, and sucrase)	Small intestine
Galactose, Glucose, Fructose		
Absorption of carbohydrates	The monosaccharides glucose, galactose, and fructose enter the capillary blood in the villi and are transported to the liver via the hepatic portal vein.	

*Oligosaccharides consist of a few linked monosaccharides.

© 2018 Pearson Education, Inc.

Foodstuff	Enzyme(s) and source	Site of action
Digestion of proteins		
Protein		
	Pepsin (stomach glands) in the presence of HCl	Stomach
Large polypeptides		
	Pancreatic enzymes (trypsin, chymotrypsin, carboxypeptidase)	Small intestine
Small polypeptides		
	Brush border enzymes (aminopeptidase, carboxypeptidase, and dipeptidase)	Small intestine
Amino acids (some dipeptides and tripeptides)		
Absorption of proteins	Amino acids enter the capillary blood in the villi and are transported to the liver via the hepatic portal vein.	

© 2018 Pearson Education, Inc.

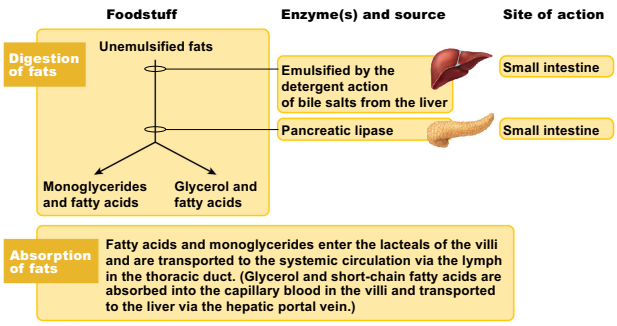

© 2018 Pearson Education, Inc.

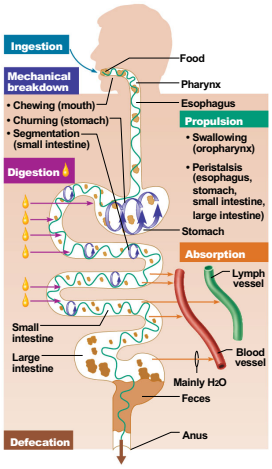

© 2018 Pearson Education, Inc.

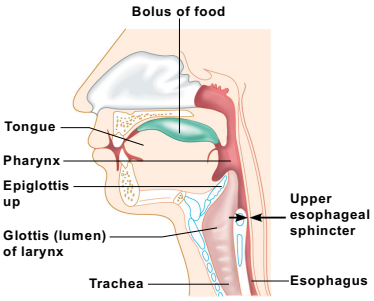

1 Upper esophageal sphincter contracted

© 2018 Pearson Education, Inc.

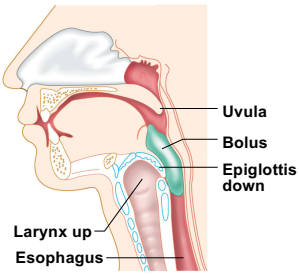

2 Upper esophageal sphincter relaxed

© 2018 Pearson Education, Inc.

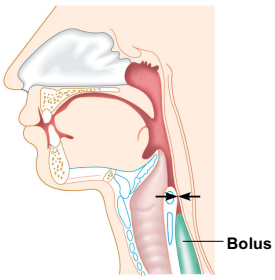

3 Upper esophageal sphincter contracted

© 2018 Pearson Education, Inc.

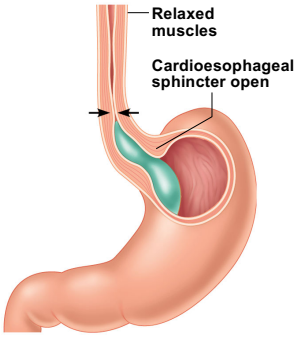

4 Cardioesophageal sphincter relaxed

© 2018 Pearson Education, Inc.

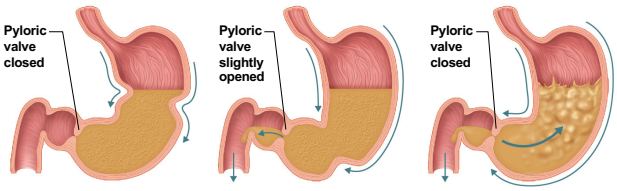

① **Propulsion:** Peristaltic waves move from the fundus toward the pylorus. → ② **Grinding:** The most vigorous peristalsis and mixing action occur close to the pylorus. The pyloric end of the stomach acts as a pump that delivers small amounts of chyme into the duodenum. → ③ **Retropulsion:** The peristaltic wave closes the pyloric valve, forcing most of the contents of the pylorus backward into the stomach.

© 2018 Pearson Education, Inc.

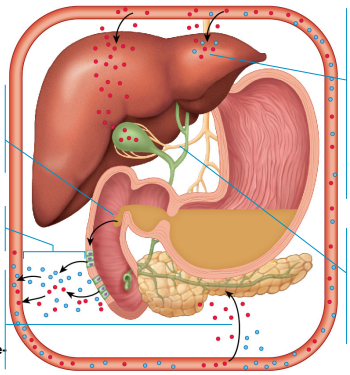

① Chyme entering duodenum causes duodenal entero-endocrine cells to release cholecystokinin (CCK) and secretin.

② CCK (red dots) and secretin (blue dots) enter the bloodstream.

③ Upon reaching the pancreas, CCK induces secretion of enzyme-rich pancreatic juice; secretin causes secretion of bicarbonate-rich pancreatic juice.

④ Secretin causes the liver to secrete more bile; CCK stimulates the gallbladder to release stored bile and the hepatopancreatic sphincter to relax (allows bile from both sources to enter the duodenum).

⑤ Stimulation by vagal nerve fibers causes release of pancreatic juice and weak contractions of the gallbladder.

© 2018 Pearson Education, Inc.

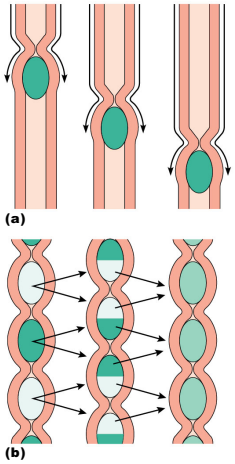

© 2018 Pearson Education, Inc.

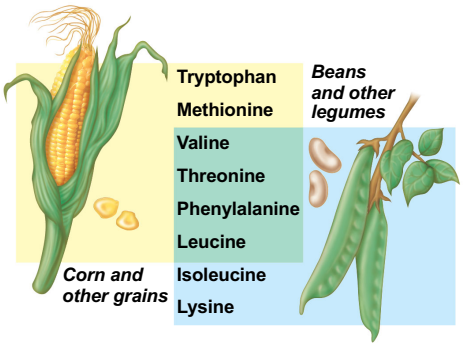

© 2018 Pearson Education, Inc.

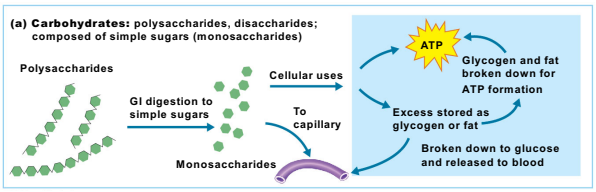

© 2018 Pearson Education, Inc.

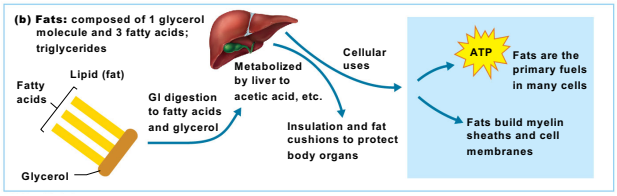

© 2018 Pearson Education, Inc.

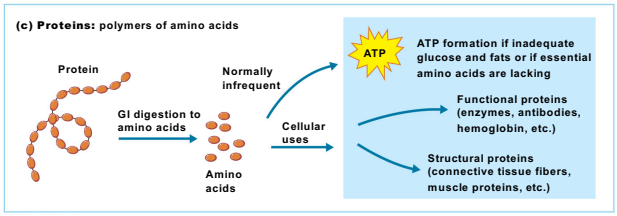

© 2018 Pearson Education, Inc.

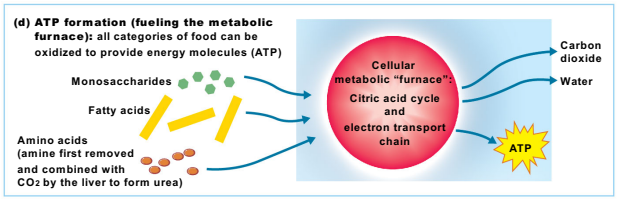

© 2018 Pearson Education, Inc.

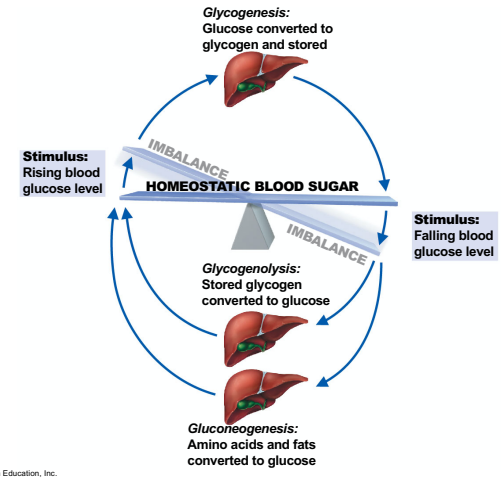

© 2018 Pearson Education, Inc.