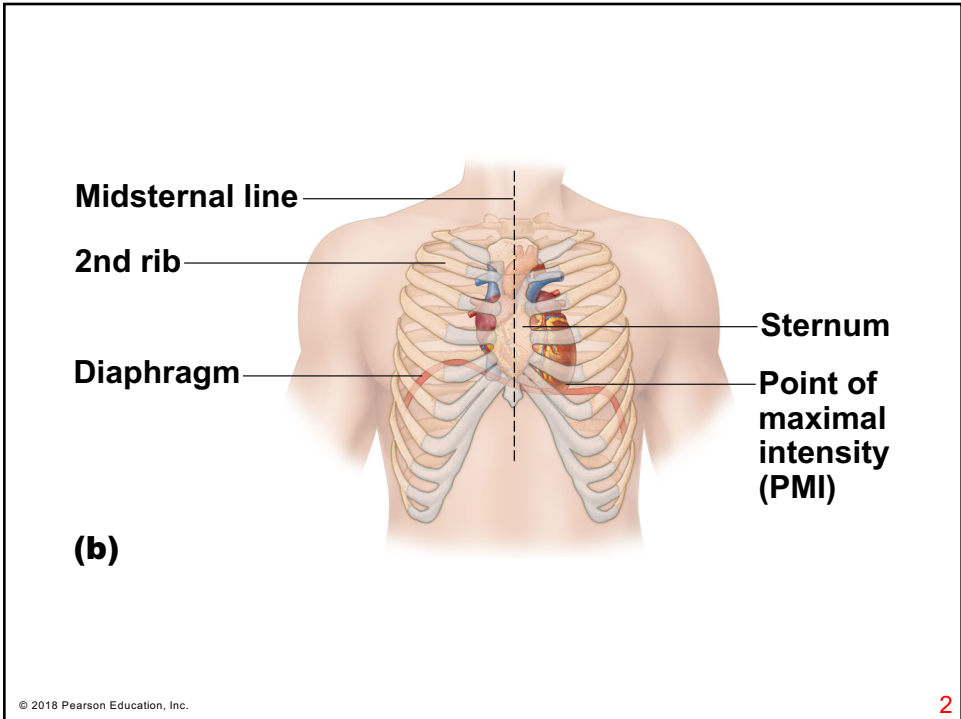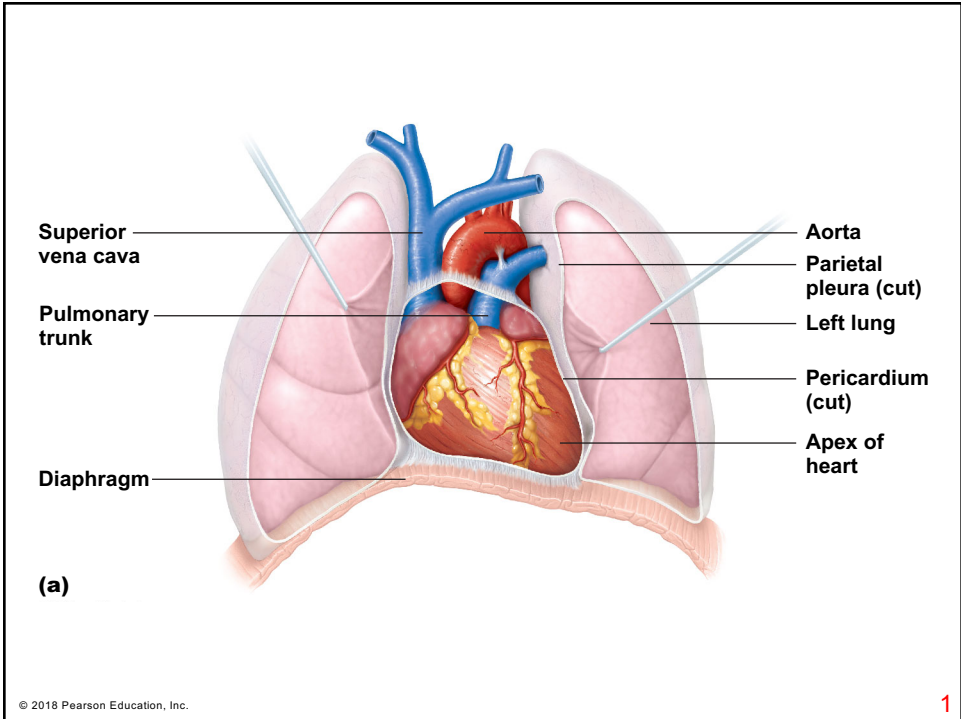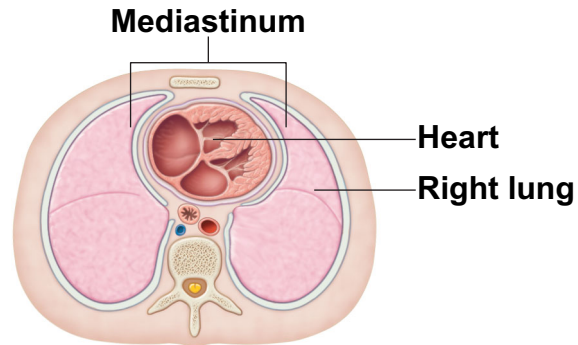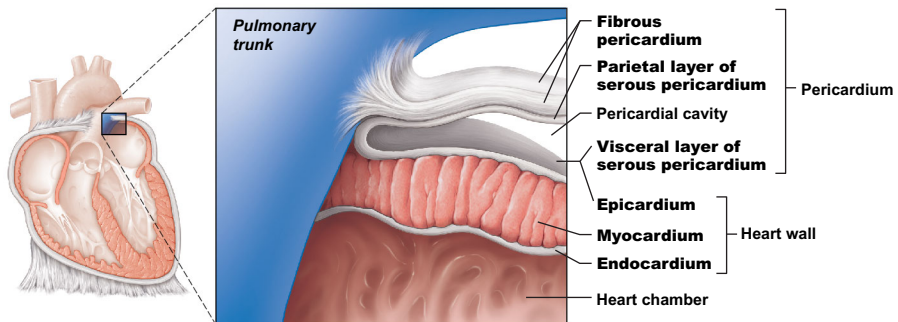
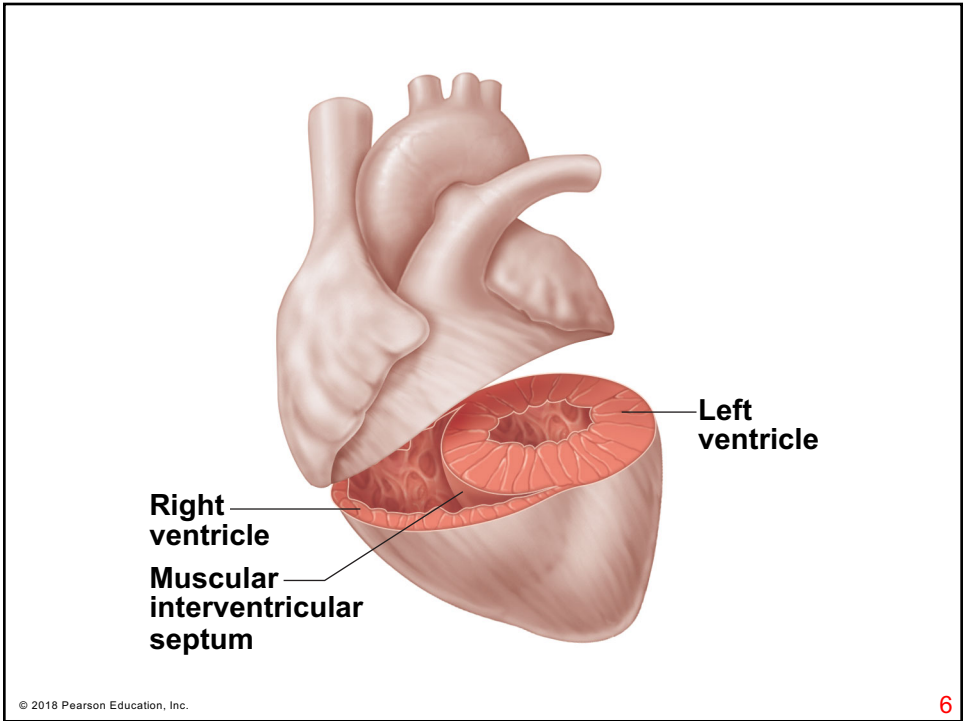
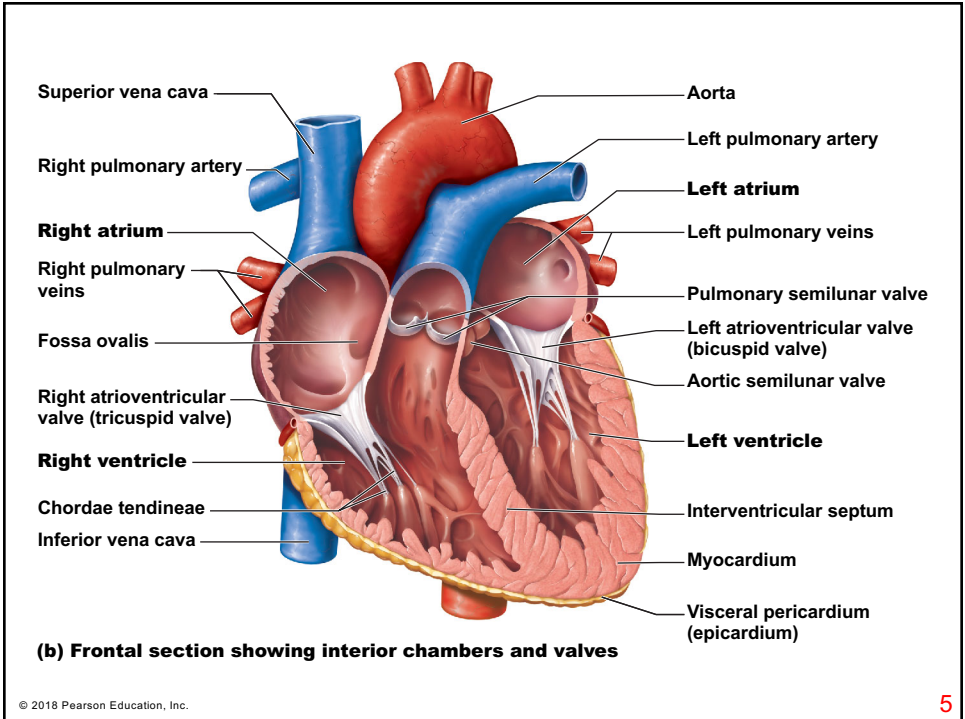
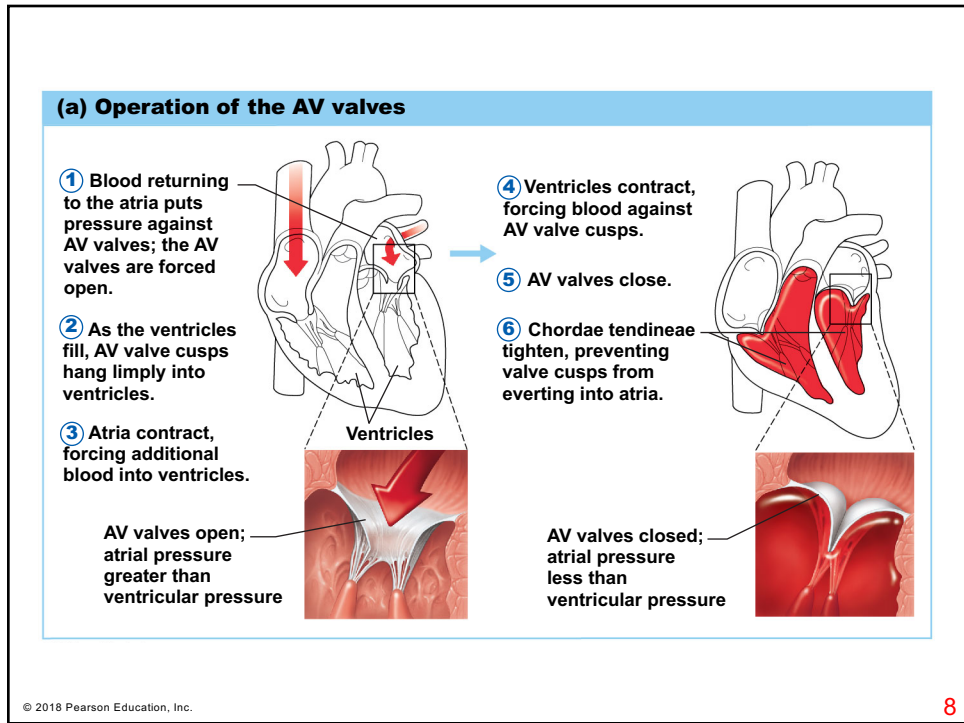
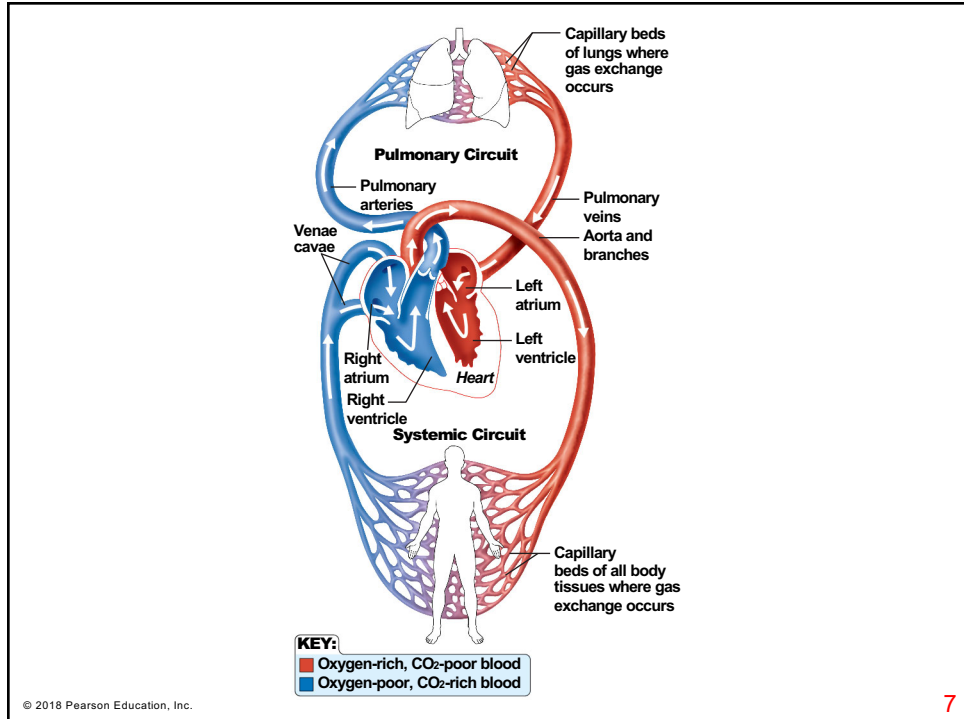


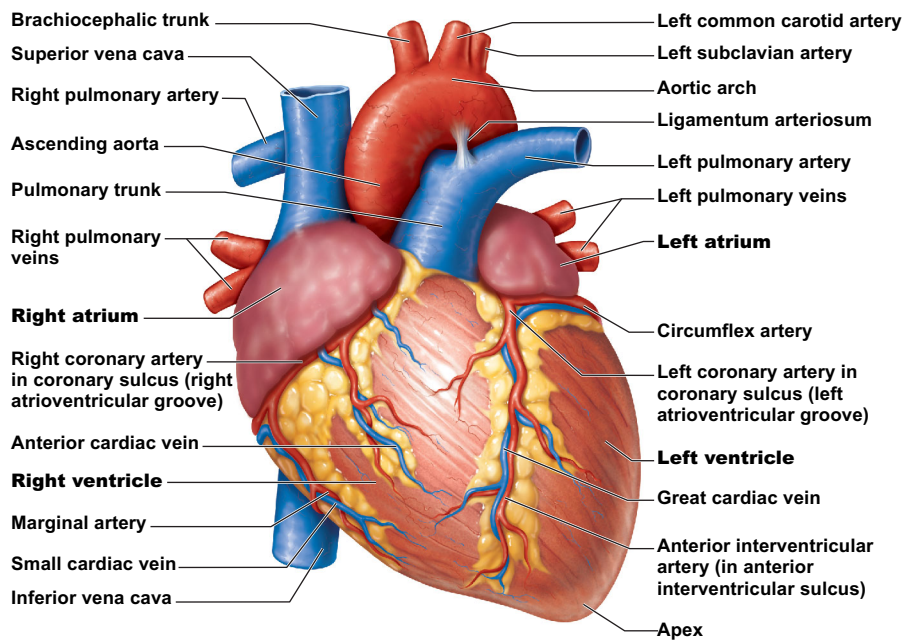
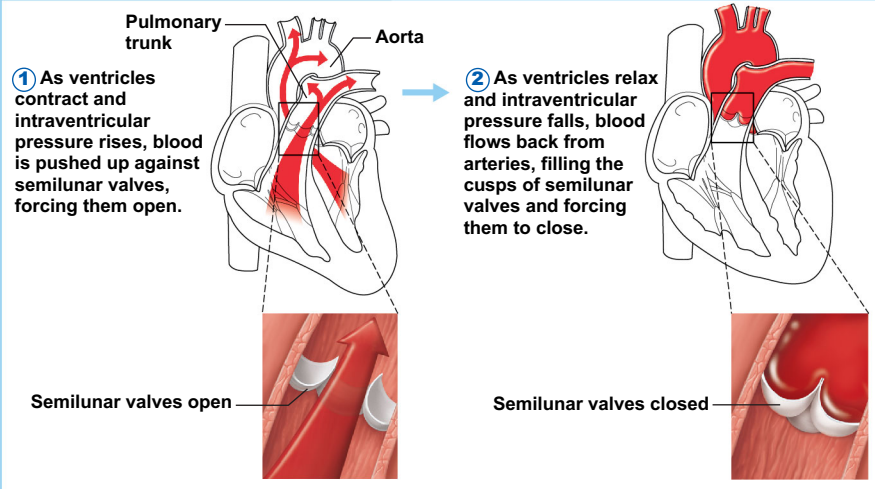
**(c) Posterior**



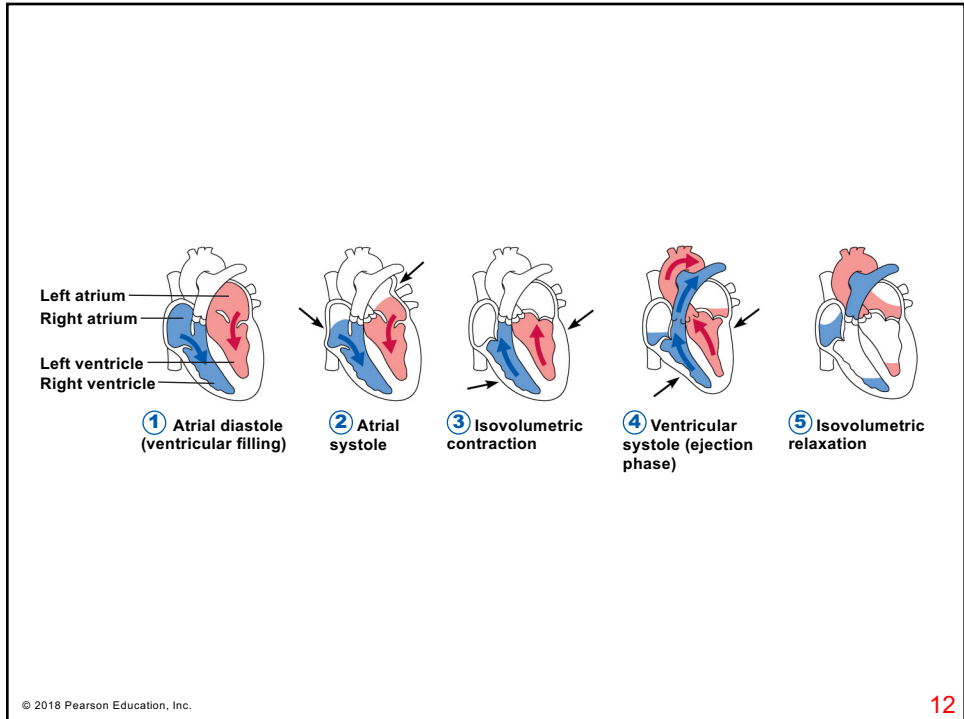
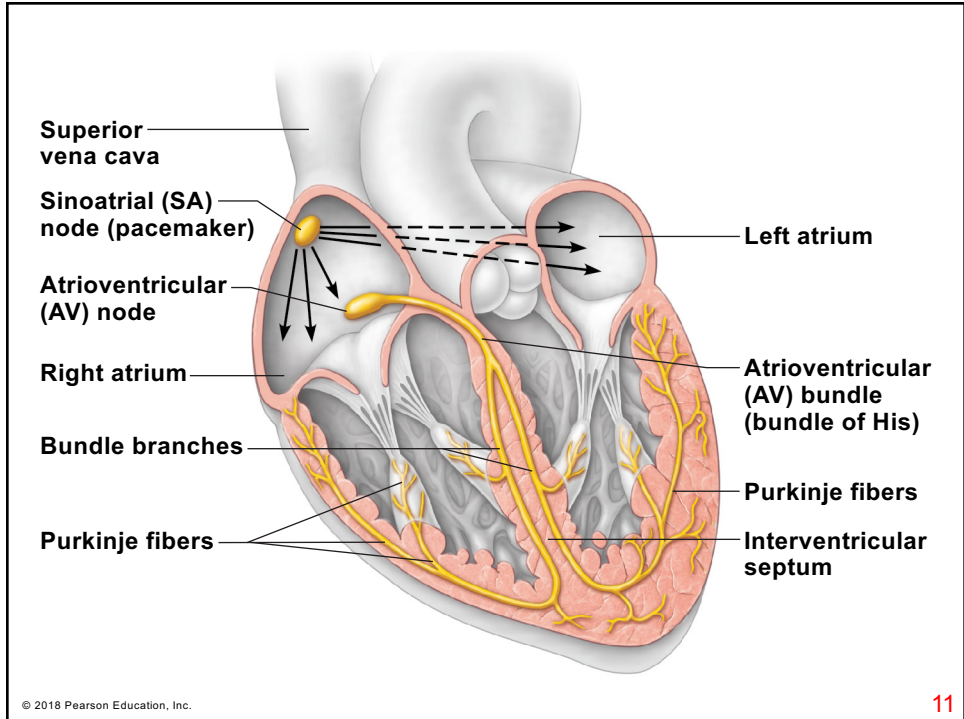


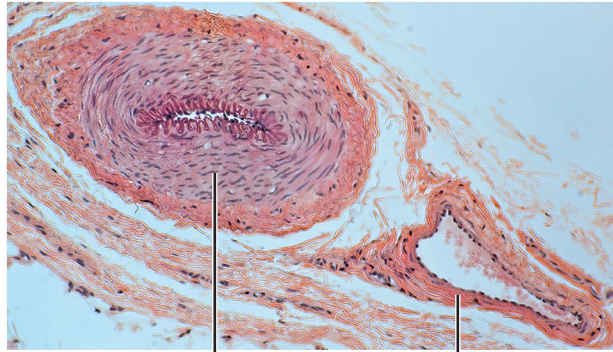


**(b) Operation of the semilunar valves**



**(a) Anterior view of heart showing major vessels**





**(a)** Artery Vein

